Cancer/Radiothérapie xxx (xxxx) xxx–xxx

Disponible en ligne sur
ScienceDirect
www.sciencedirect.com

Elsevier Masson France
EM|consulte
www.em-consulte.com

Clinical case

Late vascular complications after cranial radiotherapy: A report of two illustrative cases

Complications vasculaires tardives de la radiothérapie crânienne : rapport de deux cas illustratifs

J. Madera[a], A. Sánchez-Soblechero[b], P. Navarrete Solano[c], U. Corro Verde[c], E. Marco de Lucas[d], M. Pacheco Baldor[c], P.J. Prada[c], J. Pascual[a,*]

[a] *Service of Neurology, University Hospital Marqués de Valdecilla, University of Cantabria and IDIVAL, Av. Valdecilla s/n, 39008 Santander, Spain*
[b] *Service of Neurology, University Hospital Gregorio Marañón, Calle Doctor Esquerdo, 46, 28007 Madrid, Spain*
[c] *Service of Oncology and Radiotherapy, University Hospital Marqués de Valdecilla and IDIVAL, Av. Valdecilla s/n, 39008 Santander, Spain*
[d] *Service of Radiology, University Hospital Marqués de Valdecilla and IDIVAL, Av. Valdecilla s/n, 39008 Santander, Spain*

ARTICLE INFO

Article history:
Received 18 January 2021
Received in revised form 23 March 2021
Accepted 6 April 2021

Keywords:
Cranial radiotherapy
Mineralizing microangiopathy
SMART syndrome

ABSTRACT

Cranial radiotherapy (CRT) is used to treat a large variety of benign and malignant disorders. We present two cases of late neurological complications after CRT and briefly discuss its diagnosis and their shared pathophysiological aspects. The first case is a patient with cognitive impairment associated to mineralizing microangiopathy ten years after CRT for nasopharyngeal carcinoma and the second one is a woman with Stroke-like Migraine Attacks after Radiation Therapy (SMART) syndrome two years after CRT for anaplastic meningioma. Nowadays, higher survival rates might cause an increase in appearance of late neurological complications after CTR. These reported cases show that late complications can mimic a wide variety of neurological conditions and the importance of magnetic resonance image (MRI) to get a diagnosis.

© 2021 Société française de radiothérapie oncologique (SFRO). Published by Elsevier Masson SAS. All rights reserved.

Mots clés :
Radiothérapie crânienne
Microangiopathie minéralisante
Syndrome SMART

RÉSUMÉ

La radiothérapie crânienne est utilisée pour traiter une grande variété de maladies bénignes et malignes. Nous présentons deux cas de complications tardives après radiothérapie crânienne et discutons brièvement de leur difficile diagnostic et des aspects physiopathologiques communs des deux entités. Le premier cas est un patient atteint d'une déficience cognitive associée à une microangiopathie minéralisante, dix ans après avoir reçu une radiothérapie crânienne pour un carcinome du nasopharynx et le second cas, est une femme qui développe un syndrome SMART (*Stroke-like Migraine Attacks after Radiation Therapy*) à peine deux ans après avoir reçu une radiothérapie crânienne pour un méningiome anaplasique. L' augmentation des taux de survie entraînera à l'avenir une augmentation des complications neurologiques tardives suite à la radiothérapie crânienne. Ces deux cas rapportés sont un bon exemple dont comment ces complications tardives de la radiothérapie crânienne peuvent simuler une grande variété de maladies neurologiques et soulignent donc le rôle crucial de l'IRM dans leur diagnostic.

© 2021 Société française de radiothérapie oncologique (SFRO). Publié par Elsevier Masson SAS. Tous droits réservés.

* Corresponding author.
E-mail address: juliopascualgomez@gmail.com (J. Pascual).

https://doi.org/10.1016/j.canrad.2021.04.003
1278-3218/© 2021 Société française de radiothérapie oncologique (SFRO). Published by Elsevier Masson SAS. All rights reserved.

Please cite this article as: Madera J, et al, Late vascular complications after cranial radiotherapy: A report of two illustrative cases, Cancer Radiother, https://doi.org/10.1016/j.canrad.2021.04.003

1. Introduction

Cranial radiotherapy is used to treat a large variety of benign and malignant disorders, although the different modalities available nowadays are highly precise and safe. There are still an undeniable percentage of early and delayed neurological impairment secondary to these treatments. We present two illustrative cases of late neurological complications after CRT and briefly discuss its diagnosis and their shared pathophysiological aspects.

2. Case studies

2.1. 2.1. 1st case

This 64-year-old man was sent to our neurology department in 2019 due to a suspicion of Alzheimer's disease. He had a history of hypertension, type 2 diabetes mellitus and was diagnosed and treated in 2000 with chemoradiotherapy for nasopharyngeal carcinoma (T1N2M0). Between november 2000 and january 2001, the radiation treatment was administered in a ^{60}Co-unit TH- 780 (MDS Nordion) for the first phases and a Saturno25 linear accelerator (General Electric CGR Medical Systems) for final boost to cavum. Dose prescription was 50 Gy to prophylactic cervical lymph node chains; 66 Gy in affected nodes and 68 Gy to "cavum", fractionated 2 Gy/day. The maximum point and medium dose to cavum was 73.7 Gy and 68.65 G respectively. Due to lack of imaging used for planning (CT planning scan or X ray images) we cannot assure a precise volumetric dose received by temporal lobes, brainstem and cerebellum. However, an analysis of the information available of radiotherapy beams, diagrams and treatment fields and daily delivery notes for the treatment allow us to calculate an estimated dose to brainstem and cerebellum of 42 Gy and probably for the temporal lobes a range dose between 50–58 Gy based in typical dose distribution for 60 Co and 23 MV energy (Fig. 1).

He had begun with memory problems around 6 months earlier. His wife had noticed distractions in his daily life and difficulties to learn new activities, such as using the computer. Otherwise, he was completely functional in daily tasks. Also, his family referred to behavioural changes, mainly irascibility, in the previous year. Systemic and general neurological examination were unremarkable. Neuropsychological evaluation included a Mini-Mental State Examination (MMSE) which was completely normal (30/30), a Memory Attention Test (M@T) with a total punctuation of 37/50 (9 + 5 + 15 + 2 + 6) and a Montreal Cognitive Assessment test (MoCA-test) with a total punctuation of 23/30 (4 + 3 + 6 + 2 + 0 + 6), which points to a damage both of the delayed memory recall -that improved partially with clues- and of the visuospatial and executive abilities and language. Calcifications were seen in the brainstem in the CT scan. Cranial MRI found countless hypointense punctate lesions in susceptibility weighted imaging (SWI) involving the basal region of both temporal poles, pons and medulla oblongata, compatible with microbleeds in relation to post-radiation mineralizing microangiopathy (Fig. 2). He was diagnosed as mild cognitive impairment probably secondary to radiotherapy treatment and followed up for 18 months without either subjective or objective progression of his cognitive impairment.

2.2. 2nd case

This 55-year-old woman, smoker of ten cigarettes per day but otherwise healthy, came to our hospital in September 2017 due to progressive gait difficulties. Systemic exam was unremarkable. Neurological examination disclosed bradypsychia and left hemianopia and hypoesthesia. A big, right hemispheric mass, apparently extra-axial, was seen on the CT scan performed in the Emergency Ward. This lesion enhanced homogeneously after contrast administration, except for its cystic component. An MRI showed a right temporal extra-axial neoplasm with strong enhancement. It had a big posterior non-enhancing and non-neoplastic cyst and extensive brain edema with secondary midline shift (Fig. 3A). Tumor resection was carried out. Final pathological diagnosis was frontotemporal anaplastic meningioma (World Health Organization grade III). Follow-up MRI demonstrated a complete resection of the lesion with minor focal atrophy and a subtle area of subcortical and hyperintense area related to residual gliosis in a Fluid-Attenuated Inversion Recovery (FLAIR) sequence. Adjuvant radiation therapy was delivered to the surgical bed with Volumetric Intensity-Modulated Arc Therapy (VMAT) technique, between December 2017 and January 2018 she received a total dose of 60 Gy in 30 fractions, in a TrueBeam® lineal accelerator (Varian Medical Systems, Inc.) 2 Gy/day (Fig. 3E), with maximal dose of 63.8 Gy and median dose inside the planning treatment volume (PTV) of 60.1 Gy.

She was asymptomatic until August 2020 when began to experience daily episodes of rapidly progressive blurred vision and sometimes left numbness followed by right-sided headache lasting about 5–10 min, sometimes followed by vomiting and drowsiness. The patient was asymptomatic interictally. The frequency of these

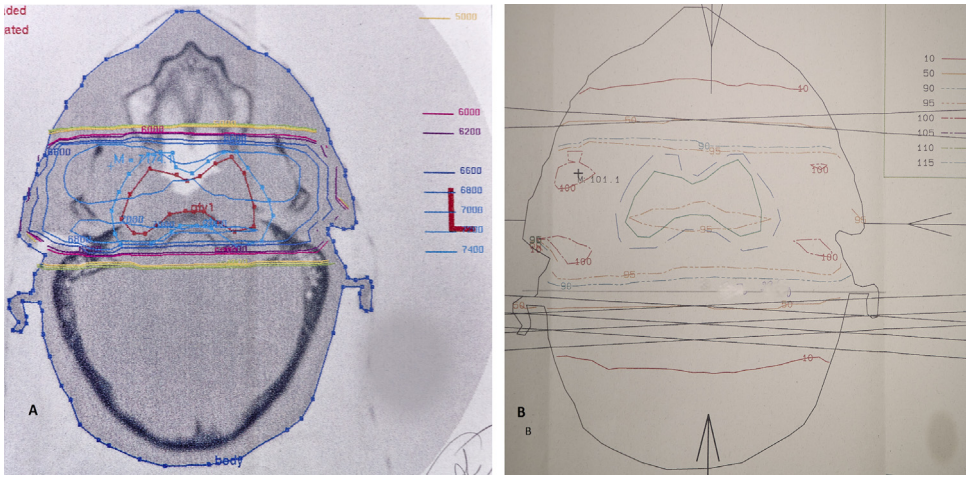

Fig. 1. Case 1: Radiotherapy planning in 2000. A, Axial CT* image at cavum level used in the planning process with PTV** contouring in green line. B. Axial diagram for the radiotherapy phases that shows PTV in red lines and the different isodoses lines for the radiotherapy treatment. The dose lines over the region of brainstem and cerebellum are also shown. *CT: Computerized tomography. **PTV: Planning Treatment Volume.

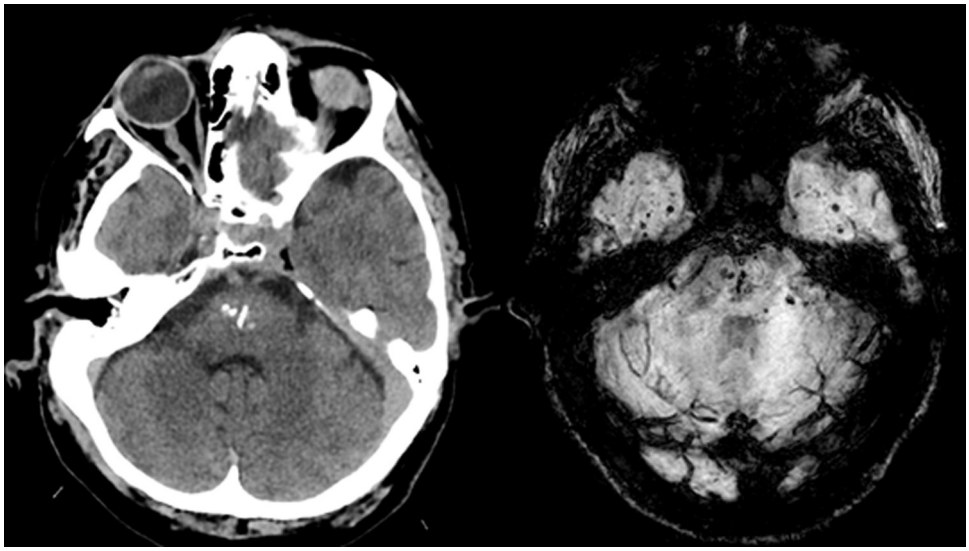

Fig. 2. Neuroimaging of Case 1: Right. Axial non-enhanced CT showing irregular calcifications in central pons. Left. MRI*** axial minimum intensity projection of venous-BOLD**** sequence disclosing innumerable blooming hypointense foci in brainstem and both temporal poles consistent with radiation-induced capillary telangiectasias and cavernous malformations (mineralizing microangiopathy). ***MRI: magnetic resonance imaging. ***Venous-BOLD: Venous-blood-oxygenation-level-dependent.

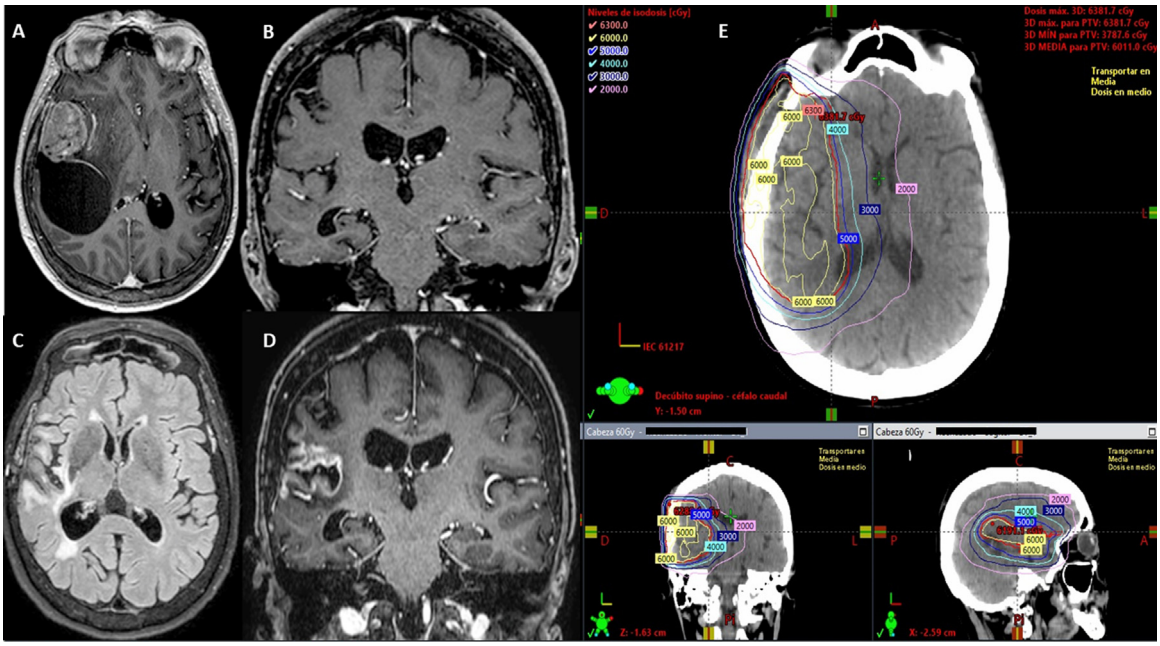

Fig. 3. Neuroimaging of Case 2. A: Enhanced axial T1-weighted image in 2017 showing an extra-axial right temporal lesion with intense and homogeneous enhancement related to meningioma with a posterior big non-neoplastic peritumoral cyst and extensive vasogenic edema. B: Enhanced coronal T1-weighted image obtained one-year after complete resection with ex-vacuo ipsilateral ventricular dilatation without anomalous cortical enhancement. C: Axial FLAIR-weighted image obtained in August 2020 disclosing edema in the posterior insular cortex with associated subcortical edema and mild sulcal effacement. D: Enhanced coronal T1-weighted image from August 2020 showing intense perisylvian cortical enhancement. E: Radiation therapy plan which shows in red line the PTV and the isodoses lines of 20 Gy*****, 30 Gy, 40 Gy, 50 Gy and 60 Gy in pink, dark blue, cyan, light blue and yellow respectively. Also shows a maximum dose point; we can see how the dose distribution is compatible with the edema zone in the next MRI after treatment. *****Gy: Gray.

episodes increased to several per day and a presumptive diagnosis of transient ischemic attacks was considered initially. Physical exam was normal except for mild mental slowness. MRI found intense enhancement of right perisylvian cortex with cortical and subcortical edema observed on FLAIR. In addition, gyral cortical hyperintensity on T1 suggestive of cortical laminar necrosis and a small area of cortical restricted diffusion in the posterior insular cortex was observed (Fig. 3 B–D). A diagnosis of SMART syndrome was considered and a cycle of oral prednisone for two weeks (beginning with 90 mg/daily) was initiated. She became asymptomatic after a few days and no new symptoms have appeared after 6 months.

3. Discussion

CRT is associated with a wide range of neurological side effects and those are divided into early toxicity such as fatigue, skin reactions, vasogenic brain edema or alopecia; and also late complications such brain atrophy, radiation necrosis, cognitive impairment, microbleeds and cavernous malformations [1]. We

show two cases of late neurological complications after CRT for primary head and neck and cranial tumors, a case of cognitive impairment associated to mineralizing microangiopathy and another case of SMART syndrome. Late toxicity after CRT mimic a variety of neurological conditions, such as an Alzheimer's disease initial phase or transient ischemic attacks as illustrated here. These cases have been shown together because they share the same pathophysiological mechanism, mainly vascular, endothelial damage with loss of oligodrendrocytes, which are the most radiation-damage prone glial cells; loss of neuronal precursors, gliosis, neuroinflammation and white matter necrosis, probably impelling each other [2].

Cerebral microbleeds are a long-term complication of past CRT and known to be related with cognitive dysfunction [2,3]. In our first case, we observed a predominant disturbance of the delayed memory recall, visuospatial and executive abilities and speech. These findings concur with those described in other patients treated with CRT for nasopharyngeal carcinoma presenting microbleeds in temporal lobes [3]. To prevent this damage it has been proposed that anti-angiogenic drugs like bevacizumab could have a radioprotective effect on microvasculature by reducing the formation of microbleeds in normal brain tissue [4].

SMART syndrome presents with recurrent and reversible focal neurological deficits including migraine with/without aura-like headache that begins some years after cranial radiotherapy for a brain tumor. Endothelial damage, due to impaired cerebrovascular autoregulation, has been suggested as the underlying reason for the appearance of focal deficits and cerebral hyperexcitability resembling migraine with aura attacks typical of SMART syndrome [5]. Even though SMART syndrome typically appears 10-20 years after CRT, cases with a shorter window period, as happened in our second case, have also been reported. SMART syndrome has been described after both focal and whole brain radiation therapy with a dosage range between 30 to 60 Gy, and usually after primary brain tumors [5,6]. Our second case expands the spectrum of SMART syndrome as it happened after an extradural tumor and only three years after CRT. Together with CRT antecedent and clinical picture, MRI is fundamental in SMART syndrome diagnosis. In all reported cases, MRI shows gyral enhancement and local edema, predominantly in temporal or occipital lobes [5–7]. In our patient, showing a *de novo* migraine with aura-like headache, MRI played a crucial role, allowing an accurate and prompt diagnosis and successful treatment with oral prednisone. Although recurrences have been reported [5,6,8], after 6 months of follow-up, no new neurological symptoms appeared in this patient.

4. Conclusions

In the last years we have observed an increase in overall survival rates in oncological patients, somehow this new reality allows us to see an increase of late neurological complications after CTR and demands a wide differential diagnosis due to the variety of symptoms. These reported cases are examples of a complex diagnostic process. Neuroimaging techniques, very especially MRI, play a fundamental role in their diagnosis and help to explain their underlying pathophysiological mechanisms. Radiation oncologists, neurologists and neuroradiologists should work together to improve management of these complications.

Disclosure of interest

The authors declare that they have no competing interest.

References

[1] Tanguturi SK, Alexander BM. Neurologic Complications of Radiation Therapy. Neurol Clin 2018;36:599–625.
[2] Kłos J, van Laar PJ, Sinnige PF, Enting RH, Kramer MCA, van der Weide HL, et al. Quantifying effects of radiotherapy-induced microvascular injury; review of established and emerging brain MRI techniques. Radiother Oncol 2019;140:41–53.
[3] Shen Q, Lin F, Rong X, Yang W, Li Y, Cai Z, et al. Temporal Cerebral Microbleeds Are Associated with Radiation Necrosis and Cognitive Dysfunction in Patients Treated for Nasopharyngeal Carcinoma. Int J Radiat Oncol Biol Phys 2016;94:1113–20.
[4] Lupo JM, Molinaro AM, Essock-Burns E, Butowski N, Chang SM, Cha S, et al. The effects of anti-angiogenic therapy on the formation of radiation-induced microbleeds in normal brain tissue of patients with glioma. Neuro Oncol 2016;18:87–95.
[5] Singh TD, Hajeb M, Rabinstein AA, Kunchok AC, Pittock SJ, Krecke KN, et al. SMART Syndrome: Retrospective Review of a Rare Delayed Complication of Radiation. Eur J Neurol 2020, http://dx.doi.org/10.1111/ene.14632 [Online ahead of print].
[6] Di Stefano AL, Berzero G, Ducray F, Eoli M, Pichiecchio A, Farina LM, et al. Stroke-like events after brain radiotherapy: a large series with long-term follow-up. Eur J Neurol 2019;26:639–50.
[7] Kerklaan JP, Lycklama Á Nijeholt GJ, Wiggenraad RGJ, Berghuis B, Postma TJ, Taphoorn MJB. SMART syndrome: A late reversible complication after radiation therapy for brain tumours. J Neurol 2011;258:1098–104.
[8] Black DF, Morris JM, Lindell EP, Krecke KN, Worrell GA, Bartleson JD, et al. Stroke-like migraine attacks after radiation therapy (SMART) syndrome is not always completely reversible: a case series. Am J Neuroradiol 2013;34:2298–303.